




# WORLD SKULL BASE E-LEARNING MATERIAL

## Otitis Media

# Otitis media

<b>Otitis media</b>	
<i>Classification and external resources</i>	
 <p>A view of the tympanic membrane showing acute otitis media</p>	
<b>ICD-10</b>	H65 <sup>[1]</sup> -H67 <sup>[2]</sup>
<b>ICD-9</b>	017.40 <sup>[3]</sup> , 055.2 <sup>[4]</sup> , 381.0 <sup>[5]</sup> , 381.1 <sup>[6]</sup> , 381.2 <sup>[7]</sup> , 381.3 <sup>[8]</sup> , 381.4 <sup>[9]</sup> , 382 <sup>[10]</sup>
<b>DiseasesDB</b>	29620 <sup>[11]</sup> serous, 9406 <sup>[12]</sup> suppurative
<b>MedlinePlus</b>	000638 <sup>[13]</sup> acute, 007010 <sup>[14]</sup> with effusion, 000619 <sup>[15]</sup> chronic
<b>eMedicine</b>	emerg/351 <sup>[16]</sup> ent/426 <sup>[17]</sup> complications, ent/209 <sup>[18]</sup> with effusion, ent/212 <sup>[19]</sup> Medical treat., ent/211 <sup>[20]</sup> Surgical treat. ped/1689 <sup>[21]</sup>
<b>MeSH</b>	D010033 <sup>[22]</sup>

**Otitis media** (Latin for "inflammation of the middle ear") is the medical term for middle ear infection. Although several subtypes of otitis media are distinguished, the term is often used synonymously with *acute otitis media*. It is very common in childhood.

## Signs and symptoms

An integral symptom of acute otitis media is ear pain; other possible symptoms include fever, and irritability (in infants). Since an acute otitis media is usually precipitated by an upper respiratory tract infection, there often are accompanying symptoms like cough and nasal discharge.<sup>[1]</sup>

## Causes

The common cause of all forms of otitis media is blockage of the Eustachian tube. This is usually due to swelling of the mucous membranes in the nasopharynx, which in turn can be caused by a viral upper respiratory infection or by allergies.<sup>[1]</sup> Because of the blockage of the Eustachian tube, the air volume in the middle ear is trapped and parts of it are slowly absorbed by the surrounding tissues, leading to a mild vacuum in the middle ear. Eventually the vacuum can reach a point where fluid from the surrounding tissues is sucked in to the middle ear's cavity (also called

tympanic cavity), causing middle ear effusion. This is seen as a progression from a Type A tympanogram to a Type C to a Type B tympanogram.

By reflux or suction of material from the nasopharynx into the normally sterile middle ear space, the fluid may then become infected - usually with bacteria. In rare cases, however, the virus that caused the initial upper respiratory tract infection can itself be identified as the pathogen causing the infection in the middle ear.<sup>[1]</sup>

## Diagnosis

As its typical symptoms overlap with other conditions, clinical history alone is not sufficient to predict whether acute otitis media is present; it has to be complemented by visualization of the tympanic membrane.<sup>[23]</sup>

To confirm the diagnosis, middle ear effusion and inflammation of the eardrum have to be identified; signs of these are fullness, bulging, cloudiness and redness of the eardrum.<sup>[1]</sup> Viral otitis may also result in blisters on the external side of the tympanic membrane, which is called *bullous myringitis* (*myringa* being Latin for "eardrum")<sup>[1]</sup>

However, sometimes even examination of the eardrum may not be able to confirm the diagnosis, especially if the canal is small and there is wax in the ear that obscures a clear view of the eardrum. Also, an upset child's crying can cause the eardrum to look inflamed due to distension of the small blood vessels on it, mimicking the redness associated with otitis media.

## Acute otitis media

Acute otitis media (AOM) is usually developing on the basis of a (viral) upper respiratory infection with blockage of the Eustachian tube and effusion in the middle ear, when the fluid in the middle ear gets additionally infected with bacteria. The most common bacteria found in this case are *Streptococcus pneumoniae*, *Haemophilus influenzae*, and *Moraxella catarrhalis*.<sup>[1]</sup>

## Otitis media with effusion

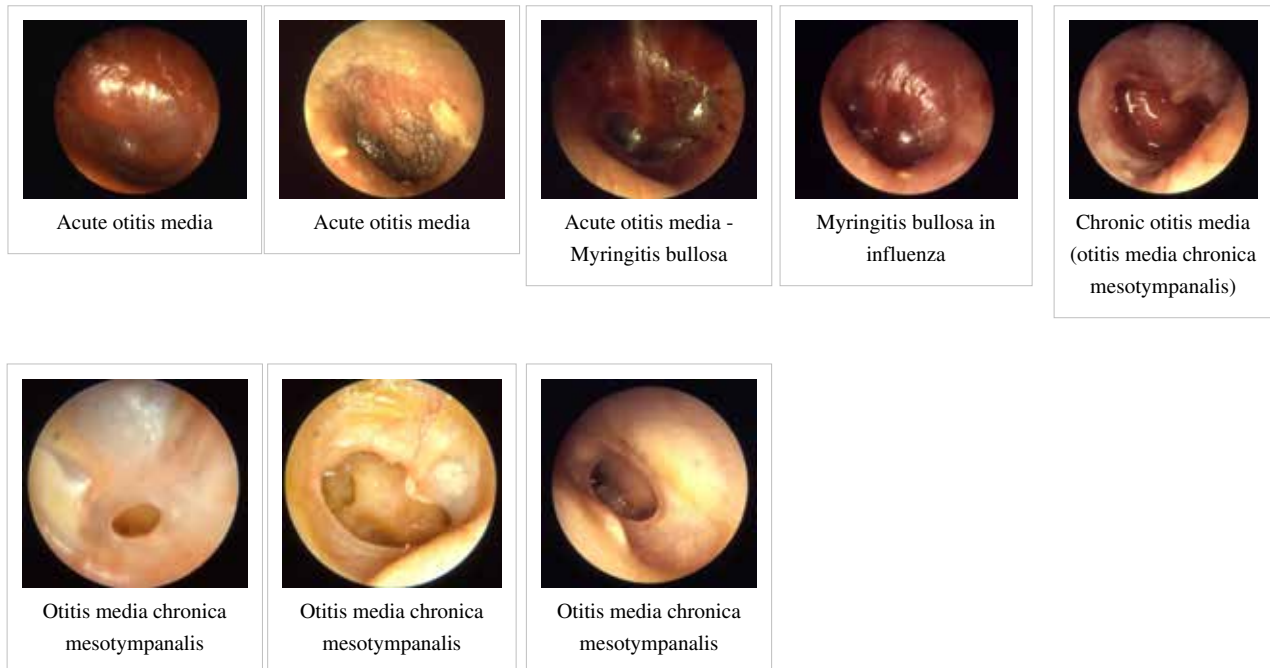
Otitis media with effusion (OME), also called serous or secretory otitis media (SOM) or glue ear,<sup>[24]</sup> is simply a collection of fluid that occurs within the middle ear space due to the negative pressure produced by altered Eustachian tube function. This can occur purely from a viral URI, with no pain or bacterial infection, or it can precede and/or follow acute bacterial otitis media. Fluid in the middle ear sometimes causes conductive hearing impairment, but only when it interferes with the normal vibration of the eardrum by sound waves. Over weeks and months, middle ear fluid can become very thick and glue-like (thus the name glue ear), which increases the likelihood of its causing conductive hearing impairment. Early-onset OME is associated with feeding while lying down and early entry into group child care, parental smoking, too short a period of breastfeeding and greater amounts of time spent in group child care increased the duration of OME in the first two years of life.<sup>[25]</sup>

## Chronic suppurative otitis media

Chronic suppurative otitis media involves a perforation (hole) in the tympanic membrane and active bacterial infection within the middle ear space for several weeks or more. There may be enough pus that it drains to the outside of the ear (otorrhea), or the purulence may be minimal enough to only be seen on examination using a binocular microscope. This disease is much more common in persons with poor Eustachian tube function. Hearing impairment often accompanies this disease.

## Adhesive otitis media

Adhesive otitis media has occurred when a thin retracted ear drum becomes sucked into the middle ear space and stuck, i.e. adherent, to the ossicles and other bones of the middle ear.



## Prevention

Long term antibiotics, while they decrease rates of infection during treatment, have an unknown effect on long term outcomes such as hearing loss.<sup>[26]</sup> They are thus not recommended.<sup>[1]</sup>

Pneumococcal conjugate vaccines when given during infancy decrease rates of acute otitis media by 6–7% and if implemented broadly would have a significant public health benefit.<sup>[27]</sup>

Certain factors such as season, allergy predisposition and presence of older siblings are known to be determinants of recurrent otitis media and persistent middle ear effusions (MEE).<sup>[28]</sup> Previous history of recurrence, environmental exposure to tobacco smoke, use of daycare, and lack of breastfeeding have all been associated with increased risk of OM development, recurrence, and persistent MEE.<sup>[29][30]</sup>

There is some evidence that breastfeeding for the first twelve months of life is associated with a reduction in the number and duration of OM infections.<sup>[31]</sup> Pacifier use, on the other hand, has been associated with more frequent episodes of AOM.<sup>[32]</sup>

Evidence does not support zinc supplementation as an effort to reduce otitis rates except maybe in those with severe malnutrition such as marasmus.<sup>[33]</sup>

## Management

Oral and topical analgesics are effective to treat the pain caused by otitis media. Oral agents include ibuprofen, paracetamol (acetaminophen), and opiates. Topical agents shown to be effective include antipyrine and benzocaine ear drops.<sup>[34]</sup> Decongestants and antihistamines, either nasal or oral, are not recommended due to the lack of benefit and concerns regarding side effects.<sup>[35]</sup>

## Antibiotics

It is important to weigh the benefits and harms before using antibiotics for acute otitis media. As over 80% of acute episodes settle without treatment, about 20 children must be treated to prevent one case of ear pain, 33 children to prevent one perforation, and 11 children to prevent one opposite side ear infection. The harms include, for every 14 children treated one child has an episode of either vomiting, diarrhea or a rash.<sup>[1]</sup> Deferring the start of antibiotics in acute otitis media for one to three days if pain is manageable with analgesics is currently recommended.<sup>[36][37]</sup>

The first line antibiotic treatment, if warranted, is amoxicillin.<sup>[1]</sup> If there is resistance or use of amoxicillin in the last 30 days then amoxicillin-clavulanate or another penicillin derivative plus beta lactamase inhibitor is recommended.<sup>[1]</sup> While less than 7 days of antibiotics have less side effects more than seven days appear to be more effective.<sup>[38]</sup> Among short-course antibiotics, long-acting azithromycin was found more likely to be successful than short-acting alternatives.<sup>[39]</sup> If there is no improvement after 2–3 days of treatment a change in therapy may be considered.<sup>[1]</sup>

## Tympanostomy tube

In chronic cases with effusions, insertion of tympanostomy tube (also called a "grommet") into the eardrum reduces recurrence rates in the 6 months after placement<sup>[40]</sup> but have little effect on long term hearing.<sup>[41]</sup> Thus tubes are recommended in those who have more than 3 episodes of acute otitis media in 6 month or 4 in a year associated with an effusion.<sup>[42]</sup>

## Alternative medicine

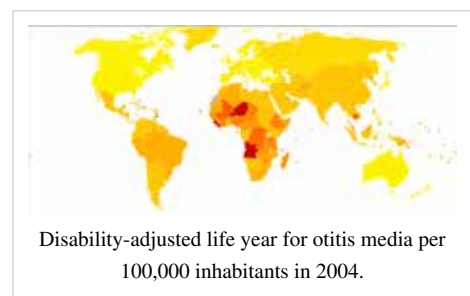
Complementary and alternative medicine is not recommended for otitis media with effusion because there is no evidence of benefit.<sup>[43]</sup> An osteopathic manipulation technique called the Galbreath technique<sup>[44]</sup> was evaluated in one randomized controlled clinical trial; one reviewer concluded that it was promising, but a 2010 evidence report found the evidence inconclusive.<sup>[45]</sup>

## Prognosis

Complications of acute otitis media consist in perforation of the ear drum, infection of the mastoid space behind the ear, or bacterial meningitis in rare cases.<sup>[11]</sup>

## Rupture

In severe or untreated cases, the tympanic membrane may rupture, allowing the pus in the middle ear space to drain into the ear canal. If there is enough of it, this drainage may be obvious. Even though the rupture of the tympanic membrane suggests a highly painful and traumatic process, it is almost always associated with the dramatic relief of pressure and pain. In a simple case of acute otitis media in an otherwise healthy person, the body's defenses are likely to resolve the infection and the ear drum nearly always heals.



## Hearing loss

Children with recurrent episodes of acute otitis media and those with otitis media with effusion or chronic otitis media, have higher risks of developing conductive and sensorineural hearing loss. Globally approximately 141 million people have mild hearing loss due to otitis media (2.1% of the population).<sup>[1]</sup> This is more common in males (2.3%) than females (1.8%).<sup>[1]</sup>

This hearing loss is mainly due to fluid in the middle ear or rupture of the tympanic membrane. Prolonged duration of otitis media is associated with ossicular complications, and together with persistent tympanic membrane perforation contributes to the severity of both the disease and the hearing loss. When a cholesteatoma or granulation tissue is present in the middle ear, the degree of hearing loss and ossicular destruction is even greater.<sup>[46]</sup>

Periods of conductive hearing loss from otitis media may have a detrimental effect on speech development in children.<sup>[47]</sup> Recent studies have also linked otitis media to educational problems, attention disorders, and problems with social adaptation.<sup>[48]</sup> Furthermore it has been demonstrated that patients suffering from otitis media have more depression/anxiety-related disorders compared to individuals with normal hearing.<sup>[49]</sup> Once the infections resolve and hearing thresholds return to normal, childhood otitis media may still cause minor and irreversible damage to the middle ear and cochlea.<sup>[50]</sup>

## Epidemiology

Acute otitis media is very common in childhood. It is the most common condition warranting medical therapy in children under five years of age in the US.<sup>[51]</sup>

## References

- [1] <http://apps.who.int/classifications/icd10/browse/2010/en#/H65>
- [2] <http://apps.who.int/classifications/icd10/browse/2010/en#/H67>
- [3] <http://www.icd9data.com/getICD9Code.ashx?icd9=017.40>
- [4] <http://www.icd9data.com/getICD9Code.ashx?icd9=055.2>
- [5] <http://www.icd9data.com/getICD9Code.ashx?icd9=381.0>
- [6] <http://www.icd9data.com/getICD9Code.ashx?icd9=381.1>
- [7] <http://www.icd9data.com/getICD9Code.ashx?icd9=381.2>
- [8] <http://www.icd9data.com/getICD9Code.ashx?icd9=381.3>
- [9] <http://www.icd9data.com/getICD9Code.ashx?icd9=381.4>
- [10] <http://www.icd9data.com/getICD9Code.ashx?icd9=382>
- [11] <http://www.diseasesdatabase.com/ddb29620.htm>
- [12] <http://www.diseasesdatabase.com/ddb9406.htm>
- [13] <http://www.nlm.nih.gov/medlineplus/ency/article/000638.htm>
- [14] <http://www.nlm.nih.gov/medlineplus/ency/article/007010.htm>
- [15] <http://www.nlm.nih.gov/medlineplus/ency/article/000619.htm>
- [16] <http://www.emedicine.com/emerg/topic351.htm>
- [17] <http://www.emedicine.com/ent/topic426.htm#>
- [18] <http://www.emedicine.com/ent/topic209.htm#>
- [19] <http://www.emedicine.com/ent/topic212.htm#>
- [20] <http://www.emedicine.com/ent/topic211.htm#>
- [21] <http://www.emedicine.com/ped/topic1689.htm#>
- [22] [http://www.nlm.nih.gov/cgi/mesh/2013/MB\\_cgi?field=uid&term=D010033](http://www.nlm.nih.gov/cgi/mesh/2013/MB_cgi?field=uid&term=D010033)

## External links

- Neff MJ (June 2004). "AAP, AAFP, AAO-HNS release guideline on diagnosis and management of otitis media with effusion" (<http://www.aafp.org/afp/2004/0615/p2929.html>). *Am Fam Physician* **69** (12): 2929–31. PMID 15222658 (<http://www.ncbi.nlm.nih.gov/pubmed/15222658>).

# Article Sources and Contributors

**Otitis media** *Source:* <http://en.wikipedia.org/w/index.php?oldid=561436606> *Contributors:* 1ForTheMoney, Abce2, Abumuteab, Adrian L James, Adrianocorno, Agmon, Akamunwa, Allgoose, AnnaP, Anthonyhole, Aonghusa85, Arcadian, Ariconte, Ariel., Art LaPella, Asav, Astavats, Aunt Entropy, AxelBoldt, BAICAN XXX, BService, Bender235, Benlissquare, Blah0401, Bmusician, Boonshofer, Booyabazooka, Borgx, C1b0rg, CL, Carlaholcombe, Chaoneng wu, Chocolateéclairé, Chriswaterguy, Chrylis, Chuckmoran7, Cowplopnmorris, Craticula, Cssiitcic, Cwmhiraeth, DSPARENT, DVdm, Davidruben, Demonte Morton, Denisarona, Diamantina, Dibberri, Dicklyon, Discospinster, Dlainhart, Dolfrog, Donner60, Dr.anthony mathews, DrSculerati, Drkarthi, EchetusXe, Elusive Pete, EmperorC, Evox777, Falcon8765, Flemnra, Fæ, G716, Galaxiaad, Galmicmi, GiggsHammouri, Gilliam, Golbez, Gordonofcartoon, Grafen, Graham87, Gsarwa, Gtarman, Guanaco, Hallows AG, Hollis1953, Hopping, Hu12, Hydrox, Icenine378, ImperfectlyInformed, Intery, James086, JamesAM, Jfdwolff, Jguad1, Jimp, Jkpkp, Jmarchn, Jmh649, Joel7687, Johnveinger, Jonathan Drain, Josabeth, Jpt1908, Justin.kirkham, Kate, Kevinb123, Kfh123, Kinema, LawyerQC, LeadSongDog, LeeRamsey, Lisae, Loisanturnbull, Loren.wilton, Loveonearth, Macaddct1984, Magister Mathematicae, Mallexikon, Manum56, Mar10029, Marknagel, Matticus78, McDutchie, Mdsctotis, MidnightRequestLine, Mikael Håggström, Mild Bill Hiccup, Milton.mic, Misodoctakleidist, Mnoke!, Moodydoody, MrOllie, Naval Scene, NawlinWiki, Nehwyn, Netha Hussain, Neutrality, Nick Number, Nikita Borisov, Nikola Lilic Jnr., Nistra, Nunh-huh, Nuno Tavares, Nv8200p, OldakQuill, Oloddin, Omnipaedista, Patulouseustachiantube, Perspeculum, Peter Chastain, Pglasziou, Philip Trueman, Pkuzel, Plrk, PurpleWyrn, RDBrown, RTC, Razorflame, Rebika92, ReedVanDeusenMD, Renato Caniatti, Rhobite, Rjwilmsi, Ronz, Rosieredfield, Ruthminlee, Rytyho usa, Sainsf, Salvio giuliano, Samw, Sggsaros, Sgt13echo, ShinyCharz, Ships at a Distance, SiarFisher, SimonArlott, Skagedal, Slicing, Soap, Sps1972, Stadler981, StephenBuxton, Stevepaget, SuperCoder, Swakeman, Swamp Ig, Tarek, Thatguyflint, The Transhumanist, Tompot, TonyW, Toyokuni3, Transity, Travis.Thurston, Trlkly, Tvarnoe, Victoriaearle, WLU, Wafulz, William Avery, Wolfmankurd, Wouterstomp, Wuzzy, Xezbeth, 55ἿἿ, 350 anonymous edits

# Image Sources, Licenses and Contributors

**File:Acute Otitis Media.jpg** *Source:* [http://en.wikipedia.org/w/index.php?title=File:Acute\\_Otitis\\_Media.jpg](http://en.wikipedia.org/w/index.php?title=File:Acute_Otitis_Media.jpg) *License:* Creative Commons Attribution-Sharealike 2.5 *Contributors:* Jmarchn, Mar10029, WhatamIdoing

**Image:Otitis media entdifferenziert2.jpg** *Source:* [http://en.wikipedia.org/w/index.php?title=File:Otitis\\_media\\_entdifferenziert2.jpg](http://en.wikipedia.org/w/index.php?title=File:Otitis_media_entdifferenziert2.jpg) *License:* Creative Commons Attribution-ShareAlike 3.0 Unported *Contributors:* B. Welleschik

**Image:Otitis media schollig.jpg** *Source:* [http://en.wikipedia.org/w/index.php?title=File:Otitis\\_media\\_schollig.jpg](http://en.wikipedia.org/w/index.php?title=File:Otitis_media_schollig.jpg) *License:* Creative Commons Attribution-ShareAlike 3.0 Unported *Contributors:* B. Welleschik

**Image:Otitis media bullös.jpg** *Source:* [http://en.wikipedia.org/w/index.php?title=File:Otitis\\_media\\_bullös.jpg](http://en.wikipedia.org/w/index.php?title=File:Otitis_media_bullös.jpg) *License:* Creative Commons Attribution-ShareAlike 3.0 Unported *Contributors:* B. Welleschik

**Image:Otitis media grippe.jpg** *Source:* [http://en.wikipedia.org/w/index.php?title=File:Otitis\\_media\\_grippe.jpg](http://en.wikipedia.org/w/index.php?title=File:Otitis_media_grippe.jpg) *License:* Creative Commons Attribution-ShareAlike 3.0 Unported *Contributors:* B. Welleschik

**Image:Otitis chron mesotymp 7.jpg** *Source:* [http://en.wikipedia.org/w/index.php?title=File:Otitis\\_chron\\_mesotymp\\_7.jpg](http://en.wikipedia.org/w/index.php?title=File:Otitis_chron_mesotymp_7.jpg) *License:* Creative Commons Attribution-ShareAlike 3.0 Unported *Contributors:* Welleschik

**Image:Otitis chron mesotymp 4.jpg** *Source:* [http://en.wikipedia.org/w/index.php?title=File:Otitis\\_chron\\_mesotymp\\_4.jpg](http://en.wikipedia.org/w/index.php?title=File:Otitis_chron_mesotymp_4.jpg) *License:* Creative Commons Attribution-ShareAlike 3.0 Unported *Contributors:* Welleschik

**Image:Otitis chron mesotymp 3.jpg** *Source:* [http://en.wikipedia.org/w/index.php?title=File:Otitis\\_chron\\_mesotymp\\_3.jpg](http://en.wikipedia.org/w/index.php?title=File:Otitis_chron_mesotymp_3.jpg) *License:* Creative Commons Attribution-ShareAlike 3.0 Unported *Contributors:* Welleschik

**Image:Otitis chron mesotymp 1.jpg** *Source:* [http://en.wikipedia.org/w/index.php?title=File:Otitis\\_chron\\_mesotymp\\_1.jpg](http://en.wikipedia.org/w/index.php?title=File:Otitis_chron_mesotymp_1.jpg) *License:* Creative Commons Attribution-ShareAlike 3.0 Unported *Contributors:* Welleschik

**Image:Otitis media world map - DALY - WHO2004.svg** *Source:* [http://en.wikipedia.org/w/index.php?title=File:Otitis\\_media\\_world\\_map\\_-\\_DALY\\_-\\_WHO2004.svg](http://en.wikipedia.org/w/index.php?title=File:Otitis_media_world_map_-_DALY_-_WHO2004.svg) *License:* Creative Commons Attribution-Sharealike 2.5 *Contributors:* Lokal\_Profil

# License

Creative Commons Attribution-Share Alike 3.0 Unported  
[//creativecommons.org/licenses/by-sa/3.0/](http://creativecommons.org/licenses/by-sa/3.0/)