



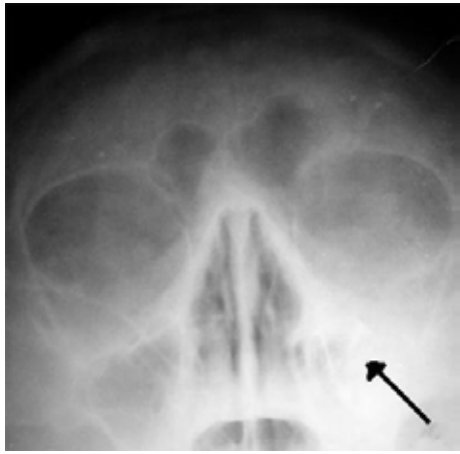
WORLD SKULL BASE E-LEARNING MATERIAL

Sinusitis

Sinusitis

Sinusitis

Classification and external resources



Left-sided maxillary sinusitis marked by an arrow. Note the absence of the air transparency indicating the presence of fluid in contrast to the other side.

ICD-10	J01 ^[1] , J32 ^[2]
ICD-9	461 ^[3] , 473 ^[4]
DiseasesDB	12136 ^[5]
MedlinePlus	000647 ^[6]
eMedicine	article/232670 ^[7]
MeSH	D012852 ^[8]

Sinusitis or **rhinosinusitis** is inflammation of the paranasal sinuses. It can be due to infection, allergy, or autoimmune issues. Most cases are due to a viral infection and resolve over the course of 10 days. It is a common condition, with over 24 million cases annually in the U.S.^[1]

Classification

Sinusitis (or rhinosinusitis) is defined as an inflammation of the mucous membrane that lines the paranasal sinuses and is classified chronologically into several categories:^[1]

- acute rhinosinusitis — a new infection that may last up to four weeks and can be subdivided symptomatically into severe and non-severe;
- recurrent acute rhinosinusitis — four or more separate episodes of acute sinusitis that occur within one year;
- subacute rhinosinusitis — an infection that lasts between four and 12 weeks, and represents a transition between acute and chronic infection;
- chronic rhinosinusitis — when the signs and symptoms last for more than 12 weeks; and
- acute exacerbation of chronic rhinosinusitis — when the signs and symptoms of chronic rhinosinusitis exacerbate, but return to baseline after treatment.

All these types of sinusitis have similar symptoms, and are thus often difficult to distinguish. Acute sinusitis is very common. Roughly ninety percent of adults have had sinusitis at some point in their life.^[9]

Acute

Acute sinusitis is usually precipitated by an earlier upper respiratory tract infection, generally of viral origin, mostly caused by rhinoviruses, coronaviruses, and influenza viruses, others caused by adenoviruses, human parainfluenza viruses, human respiratory syncytial virus, enteroviruses other than rhinoviruses, and metapneumovirus. If the infection is of bacterial origin, the most common three causative agents are *Streptococcus pneumoniae*, *Haemophilus influenzae*, and *Moraxella catarrhalis*.^[1] Until recently, *Haemophilus influenzae* was the most common bacterial agent to cause sinus infections. However, introduction of the *H. influenzae* type B (Hib) vaccine has dramatically decreased *H. influenzae* type B infections and now non-typable *H. influenzae* (NTHI) are predominantly seen in clinics. Other sinusitis-causing bacterial pathogens include *Staphylococcus aureus* and other streptococci species, anaerobic bacteria and, less commonly, gram negative bacteria. Viral sinusitis typically lasts for 7 to 10 days,^[1] whereas bacterial sinusitis is more persistent. Approximately 0.5% to 2% of viral sinusitis results in subsequent bacterial sinusitis. It is thought that nasal irritation from nose blowing leads to the secondary bacterial infection.^[10]

Acute episodes of sinusitis can also result from fungal invasion. These infections are typically seen in patients with diabetes or other immune deficiencies (such as AIDS or transplant patients on immunosuppressive anti-rejection medications) and can be life threatening. In type I diabetics, ketoacidosis can be associated with sinusitis due to mucormycosis.^[11]

Chemical irritation can also trigger sinusitis, commonly from cigarette smoke and chlorine fumes.^[12] Rarely, it may be caused by a tooth infection.^[1]

Chronic

Chronic sinusitis, by definition, lasts longer than three months and can be caused by many different diseases that share chronic inflammation of the sinuses as a common symptom. Symptoms of chronic sinusitis may include any combination of the following: nasal congestion, facial pain, headache, night-time coughing, an increase in previously minor or controlled asthma symptoms, general malaise, thick green or yellow discharge, feeling of facial 'fullness' or 'tightness' that may worsen when bending over, dizziness, aching teeth, and/or halitosis.^[1] Wikipedia:Verifiability Each of these symptoms has multiple other possible causes, which should be considered and investigated as well. Unless complications occur, fever is not a feature of chronic sinusitis.^[citation needed] Often chronic sinusitis can lead to anosmia, a reduced sense of smell.^[1] In a small number of cases, acute or chronic maxillary sinusitis is associated with a dental infection. Vertigo, lightheadedness, and blurred vision are not typical in chronic sinusitis and other causes should be investigated.

Chronic sinusitis cases are subdivided into cases with polyps and cases without polyps. When polyps are present, the condition is called chronic hyperplastic sinusitis; however, the causes are poorly understood^[1] and may include allergy, environmental factors such as dust or pollution, bacterial infection, or fungus (either allergic, infective, or reactive). Non-allergic factors, such as vasomotor rhinitis, can also cause chronic sinus problems.^[citation needed] Abnormally narrow sinus passages, such as having a deviated septum, can impede drainage from the sinus cavities and be a contributing factor.^[citation needed]

Chronic rhinosinusitis represents a multifactorial inflammatory disorder, rather than simply a persistent bacterial infection.^[1] The medical management of chronic rhinosinusitis is now focused upon controlling the inflammation that predisposes patients to obstruction, reducing the incidence of infections. However, all forms of chronic rhinosinusitis are associated with impaired sinus drainage and secondary bacterial infections. Most individuals require initial antibiotics to clear any infection and intermittently afterwards to treat acute exacerbations of chronic rhinosinusitis.

A combination of anaerobic and aerobic bacteria, are detected in conjunction with chronic sinusitis. Also isolated are *Staphylococcus aureus* (including methicilin resistant *S.aureus*) and coagulase-negative *Staphylococci* and Gram

negative enteric organisms can be isolated. Typically antibiotic treatment provides only a temporary reduction in inflammation, although hyperresponsiveness of the immune system to bacteria has been proposed as a possible cause of sinusitis with polyps (chronic hyperplastic sinusitis).^[citation needed]

Attempts have been made to provide a more consistent nomenclature for subtypes of chronic sinusitis. The presence of eosinophils in the mucous lining of the nose and paranasal sinuses has been demonstrated for many patients, and this has been termed eosinophilic mucin rhinosinusitis (EMRS). Cases of EMRS may be related to an allergic response, but allergy is not often documented, resulting in further subcategorization into allergic and non-allergic EMRS.^[13]

A more recent, and still debated, development in chronic sinusitis is the role that fungus plays in this disease. Fungus can be found in the nasal cavities and sinuses of most patients with sinusitis, but can also be found in healthy people as well.^[citation needed] It remains unclear if fungus is a definite factor in the development of chronic sinusitis and if it is, what the difference may be between those who develop the disease and those who remain free of symptoms. Trials of antifungal treatments have had mixed results.

By location

There are several paired paranasal sinuses, including the frontal, ethmoid, maxillary and sphenoid sinuses. The ethmoid sinuses is further subdivided into anterior and posterior ethmoid sinuses, the division of which is defined as the basal lamella of the middle turbinate. In addition to the severity of disease, discussed below, sinusitis can be classified by the sinus cavity which it affects:

- Maxillary – can cause pain or pressure in the maxillary (cheek) area (*e.g.*, toothache, headache) (J01.0/J32.0)
- Frontal – can cause pain or pressure in the frontal sinus cavity (located above eyes), headache (J01.1/J32.1)
- Ethmoid – can cause pain or pressure pain between/behind the eyes and headaches (J01.2/J32.2)
- Sphenoid – can cause pain or pressure behind the eyes, but often refers to the vertex, or top of the head

Recent theories of sinusitis indicate that it often occurs as part of a spectrum of diseases that affect the respiratory tract (*i.e.*, the "one airway" theory) and is often linked to asthma.^{[14][15]} All forms of sinusitis may either result in, or be a part of, a generalized inflammation of the airway, so other airway symptoms, such as cough, may be associated with it.

Signs and symptoms

Headache/facial pain or pressure of a dull, constant, or aching sort over the affected sinuses is common with both acute and chronic stages of sinusitis. This pain is typically localized to the involved sinus and may worsen when the affected person bends over or when lying down. Pain often starts on one side of the head and progresses to both sides.^[1] Acute and chronic sinusitis may be accompanied by thick nasal discharge that is usually green in color and may contain pus (purulent) and/or blood.^[1] Often a localized headache or toothache is present, and it is these symptoms that distinguish a sinus-related headache from other types of headaches, such as tension and migraine headaches. Infection of the eye socket is possible, which may result in the loss of sight and is accompanied by fever and severe illness. Another possible complication is the infection of the bones (osteomyelitis) of the forehead and other facial bones – Pott's puffy tumor.^[1]

Sinus infections can also cause inner ear problems due to the congestion of the nasal passages. This can be demonstrated by dizziness, "a pressurized or heavy head", or vibrating sensations in the head. Other symptoms of sinusitis include bad breath and Post-nasal drip.

Recent studies suggest that up to 90% of "sinus headaches" are actually migraines.^[16]^[16]Wikipedia:Verifiability The confusion occurs in part because migraine involves activation of the trigeminal nerves, which innervate both the sinus region and the meninges surrounding the brain. As a result, it is difficult to accurately determine the site from which the pain originates. Additionally, nasal congestion can be a common result of migraine headaches, due to the

autonomic nerve stimulation that can also cause tearing (lacrimation) and a runny nose (rhinorrhea).^[citation needed] A study found that patients with "sinus headaches" responded to triptan migraine medications, but stated dissatisfaction with their treatment when they are treated with decongestants or antibiotics.^[17] People with migraines do not typically have the thick nasal discharge that is a common symptom of a sinus infection.^[18]

Complications

Stage	Description
I	Preseptal cellulitis
II	Orbital cellulitis
III	Subperiosteal abscess
IV	Orbital abscess
V	Cavernous sinus septic thrombosis

The close proximity of the brain to the sinuses makes the most dangerous complication of sinusitis, particularly involving the frontal and sphenoid sinuses, infection of the brain by the invasion of anaerobic bacteria through the bones or blood vessels. Abscesses, meningitis, and other life-threatening conditions may result. In extreme cases the patient may experience mild personality changes, headache, altered consciousness, visual problems, seizures, coma, and possibly death.[□]

Sinus infection can spread through anastomosing veins or by direct extension to close structures. Orbital complications were categorized by Chandler et al.[□] into five stages according to their severity (see table). Contiguous spread to the orbit may result in periorbital cellulitis, subperiosteal abscess, orbital cellulitis, and abscess. Orbital cellulitis can complicate acute ethmoiditis if anterior and posterior ethmoidal veins thrombophlebitis enables the spread of the infection to the lateral or orbital side of the ethmoid labyrinth. Sinusitis may extend to the central nervous system, where it may cause cavernous sinus thrombosis, retrograde meningitis, and epidural, subdural, and brain abscesses.^[19] Orbital symptoms frequently precede intracranial spread of the infection . Other complications include sinobronchitis, maxillary osteomyelitis, and frontal bone osteomyelitis.^{[20][21][22][23]} Osteomyelitis of the frontal bone often originates from a spreading thrombo-phlebitis. A periostitis of the frontal sinus causes an osteitis and a periostitis of the outer membrane, which produces a tender, puffy swelling of the forehead.

The diagnosis of these complication can be assisted by noting local tenderness and dull pain, and can be confirmed by CT and nuclear isotope scanning. The most common microbial causes are anaerobic bacteria and *S. aureus*. Treatment includes performing surgical drainage and administration of antimicrobial therapy. Surgical debridement is rarely required after an extended course of parenteral antimicrobial therapy.^[24] Antibiotics should be administered for at least 6 weeks. Continuous monitoring of patients for possible intracranial complication is advised.

Causes

Factors which may predispose someone to developing sinusitis include: allergies; structural abnormalities, such as a deviated septum, small sinus ostia or a concha bullosa; nasal polyps; carrying the cystic fibrosis gene, though research is still tentative; and prior bouts of sinusitis, because each instance may result in increased inflammation of the nasal or sinus mucosa and potentially further narrow the nasal passageways.^[citation needed]

Both smoking and second hand smoke are associated with chronic rhinosinusitis.[□]

Maxillary sinusitis may also be of dental origin ("odontogenic sinusitis"),^[25] and constitutes a significant percentage (about 20% of all cases of maxillary sinusitis),[□] given the close proximity of the teeth and the sinus floor. The cause of this situation is usually a periapical or periodontal infection of a maxillary posterior tooth, where the inflammatory exudate has eroded through the bone superiorly to drain into the maxillary sinus. Once an odontogenic infection

involves the maxillary sinus, it is possible that it may then spread to the orbit or to the ethmoid sinus.^[1] Complementary tests based on conventional radiology techniques and modern technology may be indicated. Their indication is based on the clinical context.

Chronic sinusitis can also be caused indirectly through a common but slight abnormality within the auditory or Eustachian tube, which is connected to the sinus cavities and the throat. This tube is usually almost level with the eye sockets but when this sometimes hereditary abnormality is present, it is below this level and sometimes level with the vestibule or nasal entrance. This almost always causes some sort of blockage within the sinus cavities ending in infection and usually resulting in chronic sinusitis.^[citation needed]

Pathophysiology

It has been hypothesized that biofilm bacterial infections may account for many cases of antibiotic-refractory chronic sinusitis.^{[26][27][28]} Biofilms are complex aggregates of extracellular matrix and inter-dependent microorganisms from multiple species, many of which may be difficult or impossible to isolate using standard clinical laboratory techniques.^[29] Bacteria found in biofilms have their antibiotic resistance increased up to 1000 times when compared to free-living bacteria of the same species. A recent study found that biofilms were present on the mucosa of 75% of patients undergoing surgery for chronic sinusitis.^[30]

Diagnosis

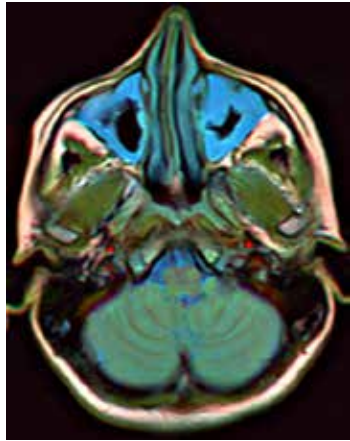
Acute

Bacterial and viral acute sinusitis are difficult to distinguish. However, if symptoms last less than 10 days, it is generally considered viral sinusitis. When symptoms last more than 10 days, it is considered bacterial sinusitis.^[1] At this point 30% to 50% of cases are bacterial.^[citation needed] Imaging by either Xray, CT or MRI is generally not recommended unless complications develop.^[1] Pain caused by sinusitis is sometimes confused for pain caused by pulpitis (toothache) of the maxillary teeth, and vice versa. Classically, the increased pain when tilting the head forwards separates sinusitis from pulpitis.

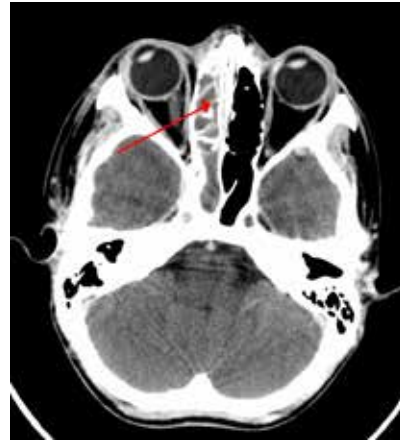Chronic

For sinusitis lasting more than 12 weeks a CT scan is recommended.^[1] Nasal endoscopy, and clinical symptoms are also used to make a positive diagnosis.^[1] A tissue sample for histology and cultures can also be collected and tested.^[31] Allergic fungal sinusitis (AFS) is often seen in people with asthma and nasal polyps. In rare cases, sinusoscopy may be made.

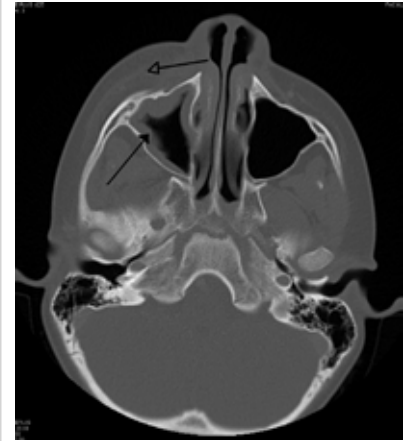
Nasal endoscopy involves inserting a flexible fiber-optic tube with a light and camera at its tip into the nose to examine the nasal passages and sinuses. This is generally a completely painless (although uncomfortable) procedure which takes between five to ten minutes to complete.



MRI image showing sinusitis. Edema and mucosal thickening appears in both maxillary sinuses.



A computed tomograph showing infection of the ethmoid sinus



Maxillary sinusitis caused by a dental infection associated with periorbital cellulitis

Treatment

Conservative

Nasal irrigation may help with symptoms of chronic sinusitis.^[32] Decongestant nasal sprays containing for example oxymetazoline may provide relief, but these medications should not be used for more than the recommended period. Longer use may cause rebound sinusitis.^[33] Other recommendations include applying a warm, moist cloth to the affected areas several times a day; drinking sufficient fluids in order to thin the mucus; and inhaling low temperature steam two to four times a day.^[34]

Antibiotics

The vast majority of cases of sinusitis are caused by viruses and will therefore resolve without antibiotics.^[1] However, if symptoms do not resolve within 10 days, amoxicillin is a reasonable antibiotic to use first for treatment^[1] with amoxicillin/clavulanate being indicated when the person's symptoms do not improve after 7 days on amoxicillin alone.^[1] Antibiotics are specifically not recommended in those with mild / moderate disease during the first week of infection due to risk of adverse effects, antibiotic resistance, and cost.^[35] Due to increasing resistance to amoxicillin the Infectious Diseases Society of America recommends amoxicillin-clavulanate as the treatment of choice for acute sinusitis.^[1] They also recommend against other commonly used antibiotics, including azithromycin, clarithromycin and trimethoprim/sulfamethoxazole, because of growing drug resistance.^[1]

Fluoroquinolones, and a newer macrolide antibiotic such as clarithromycin or a tetracycline like doxycycline, are used in those who have severe allergies to penicillins.^[36] Because of increasing resistance to amoxicillin the 2012 guideline of the Infectious Diseases Society of America recommends amoxicillin-clavulanate as the initial treatment of choice for bacterial sinusitis.^[1] The guidelines also recommend against other commonly used antibiotics, including azithromycin, clarithromycin and trimethoprim/sulfamethoxazole, because of growing drug resistance.

A short-course (3–7 days) of antibiotics seems to be just as effective as the typical longer-course (10–14 days) of antibiotics for those with clinically diagnosed acute-bacterial sinusitis without any other severe disease or complicating factors.^[37] The IDSA guideline suggest five to seven days of antibiotics is long enough to treat a bacterial infection without encouraging resistance. The guideline still do recommend children receive antibiotic treatment for 10 days to two weeks.^[1]

Corticosteroids

For unconfirmed acute sinusitis, intranasal corticosteroids have not been found to be better than placebo either alone or in combination with antibiotics.^[1] For cases confirmed by radiology or nasal endoscopy, treatment with corticosteroids alone or in combination with antibiotics is supported.^[38] The benefit however is small.^[39]

There is only limited evidence to support short treatment with oral corticosteroids for chronic rhinosinusitis with nasal polyps.^[40]

Surgery

For chronic or recurring sinusitis, referral to an otolaryngologist specialist may be indicated, and treatment options may include nasal surgery. Surgery should only be considered for those patients who do not experience sufficient relief from optimal medication.^[41]

Maxillary antral washout involves puncturing the sinus and flushing with saline to clear the mucus. A 1996 study of patients with chronic sinusitis found that washout confers no additional benefits over antibiotics alone.^[42]

A number of surgical approaches can be used to access the sinuses and these have generally shifted from external/extranasal approaches to intranasal endoscopic ones. The benefit of Functional Endoscopic Sinus Surgery (FESS) is its ability to allow for a more targeted approach to the affected sinuses, reducing tissue disruption, and minimizing post-operative complications.^[43]

Another recently developed treatment is balloon sinuplasty. This method, similar to balloon angioplasty used to "unclog" arteries of the heart, utilizes balloons in an attempt to expand the openings of the sinuses in a less invasive manner. The utility of this treatment for sinus disease is still under debate but appears promising.^[citation needed]

For persistent symptoms and disease in patients who have failed medical and the functional endoscopic approaches, older techniques can be used to address the inflammation of the maxillary sinus, such as the Caldwell-Luc radical antrostomy. This surgery involves an incision in the upper gum, opening in the anterior wall of the antrum, removal of the entire diseased maxillary sinus mucosa and drainage is allowed into inferior or middle meatus by creating a large window in the lateral nasal wall.^[44]

Epidemiology

Sinusitis is a common condition, with between 24–31 million cases occurring in the United States annually.^[45] Chronic sinusitis affects approximately 12.5% of people.^[1]

Research

Based on recent theories on the role that fungus may play in the development of chronic sinusitis, antifungal treatments have been used, on a trial basis. These trials have had mixed results.^[1]

References

- [1] <http://apps.who.int/classifications/icd10/browse/2010/en#/J01>
- [2] <http://apps.who.int/classifications/icd10/browse/2010/en#/J32>
- [3] <http://www.icd9data.com/getICD9Code.aspx?icd9=461>
- [4] <http://www.icd9data.com/getICD9Code.aspx?icd9=473>
- [5] <http://www.diseasesdatabase.com/ddb12136.htm>
- [6] <http://www.nlm.nih.gov/medlineplus/ency/article/000647.htm>
- [7] <http://emedicine.medscape.com/article/232670-overview>
- [8] http://www.nlm.nih.gov/cgi/mesh/2013/MB_cgi?field=uid&term=D012852
- [25] The maxillary sinusitis of dental origin: From diagnosis to treatment (<http://www.lecourrierdudentiste.com/dossiers-du-mois/les-sinusites-maxillaires.html>) Le courrier du dentiste
- [31] Harrison's Manual of Medicine 16/e

[44] Bailey and Love

External links

- Sinusitis (http://www.dmoz.org/Health/Conditions_and_Diseases/Ear,_Nose_and_Throat/Nose_and_Paranasal_Sinuses/Sinusitis/) at the Open Directory Project

Article Sources and Contributors

Sinusitis *Source:* <http://en.wikipedia.org/w/index.php?oldid=561749475> *Contributors:* "alyosha", (aeropagitica), 2003:51:AE07:2901:223:32FF:FE9E:F9D6, 2004-12-29T22:45Z, 207-203-156-105, 212.159.166.xxx, 62.30.0.xxx, AS, AVRS, Abataasis, Aceventura1368, Aeroblaster3, Ageekgal, Ahoerstemeier, Alanna91, Alansohn, All Is One, Alphawiki007, Alteripse, AnThRaX Ru, Andrewman327, Angelito7, Anim8cme, AnnaFrance, Anthonycole, Arcadian, Arisa, Arthema, Arunsingh16, AtticusX, AugPi, BSW-JMH, BService, Badgettrg, BarretB, Bernfarr, Besselfunctions, BirdValiant, Bizzurp, BlackRaspberry, Blueraspberry, Bmschulman, BogieBop, Boonshofer, Borgx, Bpeps, Brona, Bryan Derksen, Bunnyhero, Caesarjbsquitti, Cafe77, Capricorn42, Catseyefordetail, Cherylrenee, Chicocvenancio, Chris Capoccia, ClevelandClinicCME, Clicketyclack, Cmckain14, CommonsDelinker, Conversion script, Cremepuff222, Crohnie, DRPIYUSH442, DVD R W, DanielRigal, DarkFalls, Darth Mike, David Eppstein, David Zemeckis, David.hilton.p, Davidruben, Dbalnaves, Decembermouse, Denes.gal, Diego Grez, Diiscool, Dina, Doctorsclinic, Doczilla, Donner60, Download, Dr.enh, Dream Focus, Drgarden, Dribrook, Drugrep, Durova, E4043, Edgarpoe, Edward, Eeekster, Egil, Eleassar, Entconsultw, Epr123, ExRat, FILWISE, Farzaneh, Flowanda, FrankTobia, Fresheneesz, Frymaster, G716, Gaius Cornelius, Ganesh Paudel, Georgelazenby, Gggh, Gilliam, Gino.bdmg, Gjs238, Glenalpine, GoingBatty, Gongshow, GrEp, Graham87, Grockl, Hadal, HectorH, Hoffmeier, Hoof Hearted, Hooriaj, Horatiot burns, Hu12, Ian Donaldson, Ian Gottherd, ImGz, ImperfectlyInformed, Infections, Ingolfson, Ino5hiro, Invertzoo, Ip412, J.delanoy, JaGa, Janto, Jasonstoesser, Jay, Jayelani, JeffreyY, Jennavecia, JenniStinson, Jereback, Jesse Viviano, Jfdwolff, Jk2q3jrklse, Jmarchn, Jmh649, John, John Mackenzie Burke, Johnniq, Johnveinger, Josherdoogin, Juliancolton Alternative, Jvannaarden, Jvineberg, Jwy, Katalaveno, Kbdank71, Kbh3rd, Kenyon58, Kiddoooooooooooo, Klausness, Kliidiplomus, Ko1, Kpjas, Krash, Lalituor, Lawikitejana, LeadSongDog, Lesion, Libbee96, Lotic, M.thorihan, Mahmudmasri, Manojt, Marknew, MastCell, Materialscientist, Mauls, Mazarin07, McSly, Mdwyer, Medglu, Medhelper, Mewulwe, Mflocthero, Michael Hardy, Mk5384, Mlaffs, Mr-Natural-Health, MrADHD, Mschlindwein, Murtasa, Mwtoews, Nakon, Nappyyrootslistener, Naturesritermedies, Nehwyn, Neo., Neon1000, Nevit, NewEnglandYankee, Nick Number, Nihiltres, No One of Consequence, Nono64, Notmicro, Ohnoitsjamie, Omnipotentsg, Oneiros, Oobopshark, Orangemarlin, Orangepie100, Osm agha, Pablo X, PaperTruths, Pawl Kennedy, Pennstatephil, PeterGrecian, PetrB, Pgr94, Philippe (WMF), PigFlu Oink, PrimeHunter, RDBrown, Rdsmith4, RexNL, Rinpoche, Rjwilmsi, RobinHood70, Romann, RoseParks, Rosscoloco, Rotherpe, Rustavo, SHouser, Saga City, Sainsf, Sanspeur, Sarindam7, Saylormd, Schmlouf, Scott5114, Sdlitvin, Shadowofdeath1232, Sidrawal, Silvermask, Silvonen, SimonD, SinisterE, Sinusdynamics, Sinustreat, Skagedal, SkyWalker, Smalljim, Sofiabenne, Somedifferentstuff, Spencercpayne, Srilal728, Stealthphreak, StormWillLaugh, SuW, Sunuwash, SwisterTwister, Swtrb1555, Taemyr, Tea with toast, Tepl, Tfgrt1, The Thing That Should Not Be, Thek826, Tins128, TipPt, Todd cross-watson, Tom.erez, TomRitchford, Truehawk, Trump22, Unara, Uthbrian, Valkyryn, Verbal, Vfp15, Vsion, WLU, WacoJacko, Wafflephile, Wafulz, Watermelon mang, Wham Bam Rock II, Woodcore, Wouterstomp, Writ Keeper, Wxidea, Xasodfuih, Xigglelee, Yobol, ZacBowling, Zachlipton, Zero sharp, Zro, Zzuuzz, Δ, Александр, 543 anonymous edits

Image Sources, Licenses and Contributors

File:Maxilar sinusites.jpg *Source:* http://en.wikipedia.org/w/index.php?title=File:Maxilar_sinusites.jpg *License:* Public Domain *Contributors:* Alex Khimich

File:Brain MRI 112010 rgbca.png *Source:* http://en.wikipedia.org/w/index.php?title=File:Brain_MRI_112010_rgbca.png *License:* unknown *Contributors:* Nevit Dilmen (talk)

File:Ethmoidinfection.png *Source:* <http://en.wikipedia.org/w/index.php?title=File:Ethmoidinfection.png> *License:* Creative Commons Attribution-Sharealike 3.0 *Contributors:* User:Jmh649

File:RtmaxobitinfecctteethCT.png *Source:* <http://en.wikipedia.org/w/index.php?title=File:RtmaxobitinfecctteethCT.png> *License:* Creative Commons Attribution-Sharealike 3.0 *Contributors:* User:Jmh649

License

Creative Commons Attribution-Share Alike 3.0 Unported
[//creativecommons.org/licenses/by-sa/3.0/](http://creativecommons.org/licenses/by-sa/3.0/)