



WORLD SKULL BASE E-LEARNING MATERIAL

Functional Endoscopic Sinus Surgery

Functional endoscopic sinus surgery

Functional endoscopic sinus surgery (FESS) is the mainstay in the surgical treatment of sinusitis and nasal polyps, including bacterial, fungal, recurrent acute, and chronic sinus problems. Ample research supports its record of safety and success. FESS is a relatively recent surgical procedure that uses nasal endoscopes (using Hopkins rod lens technology) through the nostrils to avoid cutting the skin. FESS came into existence through the pioneering work of Drs. Messerklinger and Stamberger (Graz, Austria). Other surgeons have made additional contributions (first published in USA by Kennedy in 1985).^[1] A Cochrane review in 2006, based on three randomized control trials (Fairley 1993, Hartog 1997, and Ragab 2004) concluded that there was no significant difference in cure rates comparing FESS to other treatment methods. A meta-analysis of these three studies was not used as the studies did not have a single disease staging system, a single FESS procedure or uniform outcomes measures. Fairley 1993 found no significant difference between FESS and inferior meatal antrostomy in regards to symptoms score (weighted mean difference (WMD) 1.37, $p=0.6$). Hartog 1997 found no statistically significant difference in cure rates at 1 year when comparing FESS to nasal irrigation alone (odds ratio 1.63, $P = 0.35$). Ragab 2004 found no significant difference in total symptoms score at one year between FESS and medical treatment alone (WMD 1.20, $P = 0.86$). Hartog 1997 found a relapse rate of 2.4% in FESS and sinus irrigation group and 5.6% relapse rate in sinus irrigation only group (RRR=0.571, NNT = 32). The other studies did not mention relapse rate.^[2]

Technique

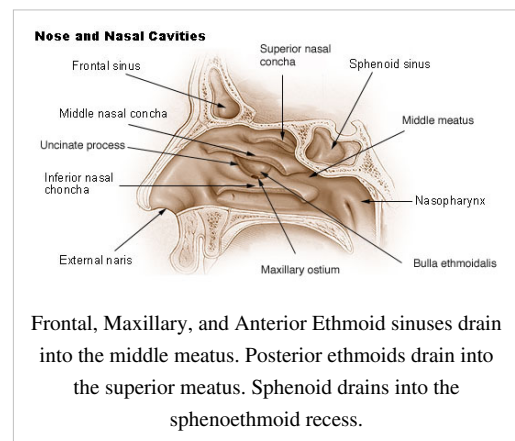
Telescopes with diameters of 4mm (adult use) and 2.7mm (pediatric use) and with a variety of viewing angles (0 degrees to 30, 45, 70, 90, and 120 degrees) provide good illumination of the inside of the nasal cavity and sinuses. High definition cameras, monitors and a host of tiny articulating instruments aid in identifying and restoring the proper drainage and ventilation relationships between the nose and sinus cavities. Cultures (putting abnormal sinus secretions into an incubator to check for bacteria and fungi) and biopsies (examining small bits of tissue under a microscope) can be easily obtained to yield valuable diagnostic information to guide postoperative therapy for optimal long term results.

All the sinuses can be accessed at least to some degree by means of this surgery: The frontal sinuses located in the forehead, the maxillary sinuses in the cheeks, the ethmoid sinuses between the eyes, and the sphenoid sinuses located in the back of the nasal cavity at the base of the skull.

Extended approaches

Endoscopic access to pituitary tumors, where an ear, nose and throat surgeon works together with a neurosurgeon, has been successfully accomplished for many years. More recently, further specialization combined with advanced training and techniques have allowed the paranasal sinuses to be a relatively low-morbidity approach to selected tumors even inside the skull or brain. This can be divided into:

- approaches to the anterior cranial fossa
- approaches to the mid cranial fossa
- approaches to the posterior cranial fossa
- access to the infratemporal fossa (incl. pterygopalatine fissure)
- access to the sella turcica



- orbital access
- optic nerve access

Complications

Extreme care is required with this surgery due to the proximity of the sinuses to the eyes, optic nerves, brain and internal carotid arteries. However, these possible serious risks are rare occurrences and there are potentially many benefits from a well-performed endoscopic sinus surgery with appropriate indications. While a surgeon must have adequate training and experience to manage the procedure, endoscopic sinus surgery is one of the most common procedures performed day to day by the average ear, nose and throat specialist physician in private practice.

CT navigation

Computed tomography (CT) navigation is a tool that may be used by surgeons to better correlate surgical anatomy with pre-operative CT imaging. A computer is used to identify the 3-dimensional location of a probe tip placed within the patient's nose or sinuses. Bleeding, disease processes and anatomical variants among individuals can alter a surgeon's view of landmarks during surgery. Hence, CT-navigational assistance in sinus surgery is used to improve anatomical identification and avoid damage to vital neighboring structures such as the brain and eyes.

Definitive proof that CT navigation improves outcomes and decreases complications is lacking. A Swedish study of 212 patients undergoing sphenoidectomy published in 2008 concluded that the clinical success of the procedure was similar with or without the use of CT navigation, and that the rate of complications might be slightly reduced.^[3]

References

Article Sources and Contributors

Functional endoscopic sinus surgery *Source:* <http://en.wikipedia.org/w/index.php?oldid=546912099> *Contributors:* Ageekgal, Clicketyclack, Dozenist, Erik.weitzel, Eugene-elgato, Eumolpo, FeatherPluma, Filip kocha matgosię, G-my, Ggomez113, Golbez, Huckfinne, Janko, Manojt, Msrbl49, Nick Number, Nono64, Ph.eyes, Postcard Cathy, RDBrown, Rjwilmsi, Ryan Roos, The Letter J, WhatamIdoing, Wouterstomp, Zowgin, 33 anonymous edits

Image Sources, Licenses and Contributors

Image:Illu_nasal_cavities.jpg *Source:* http://en.wikipedia.org/w/index.php?title=File:Illu_nasal_cavities.jpg *License:* Public Domain *Contributors:* Erik.weitzel

License

Creative Commons Attribution-Share Alike 3.0 Unported
[//creativecommons.org/licenses/by-sa/3.0/](http://creativecommons.org/licenses/by-sa/3.0/)
